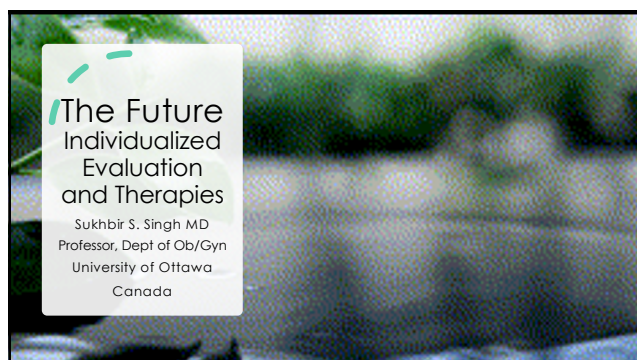
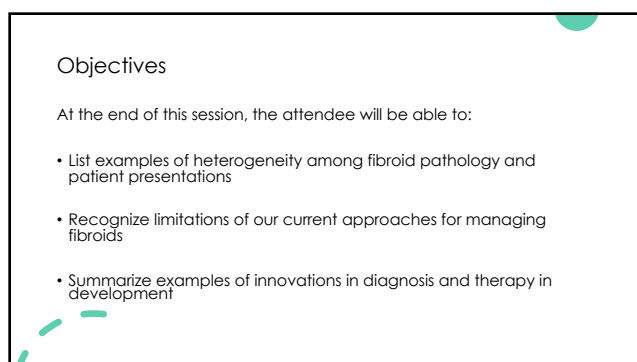




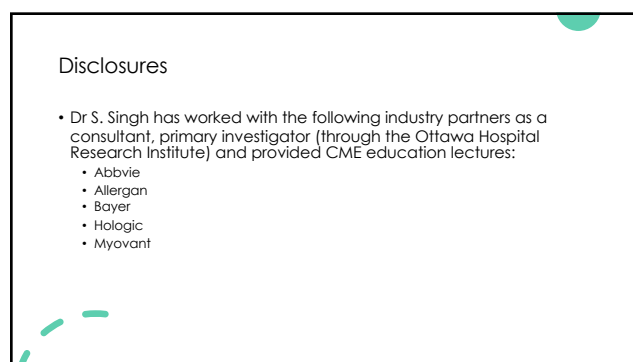
1



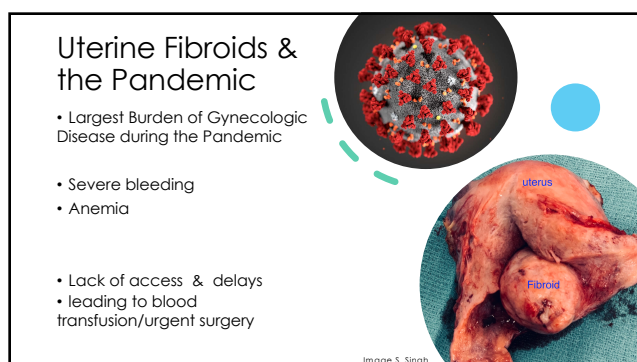
2



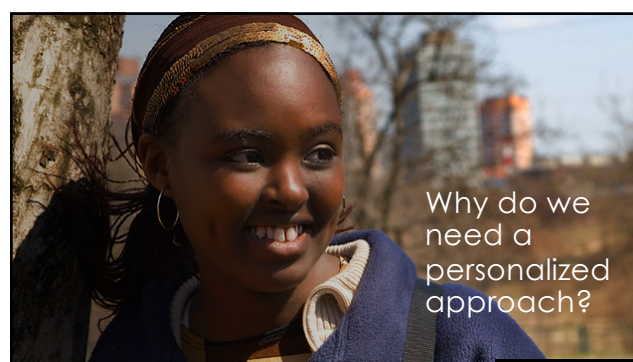
3



4



6



7

# The Case for a Personalized Approach

Variations in Disease –  
Fibroids are NOT ALL the SAME

Variable Impact

Presence of “sibling” conditions

8

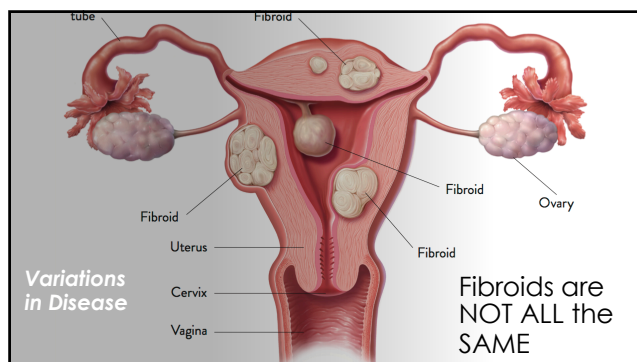
# The Case for a Personalized Approach

**Variations in Disease**

Variable Impact

Presence of “sibling” conditions

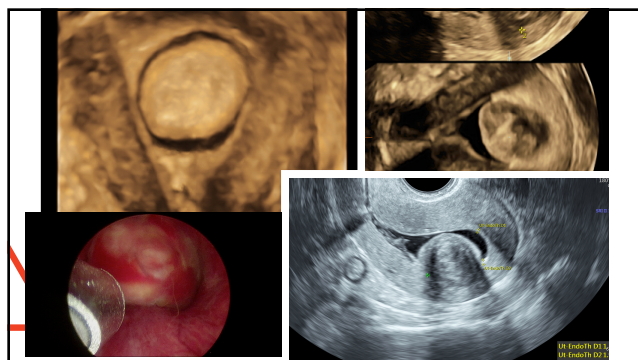
9



11

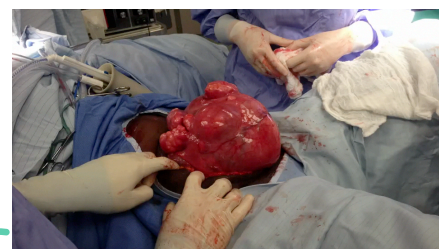

12



13

And then there are Fibroids...



14



Polyp			
Adenomyosis	Submucosal		
Leiomyoma	Other		
Malignancy & Hyperplasia			

Coagulopathy	
Ovulatory Dysfunction	
Endometrial	
Iatrogenic	
Not Yet Classified	

### Leiomyoma Subclassification System

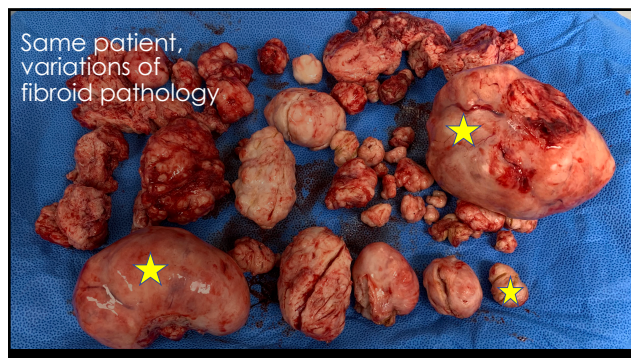SM- Submucosal	0	Pedunculated Intracavitary
	1	<50% Intramural
	2	≥ 50% Intramural
	3	Contacts endometrium; 100% Intramural
0- Other	4	Intramural
	5	Subserosal ≥50% Intramural
	6	Subserosal < 50% Intramural
	7	Subserosal Pedunculated
	8	Other (specify eg. cervical, parasitic)

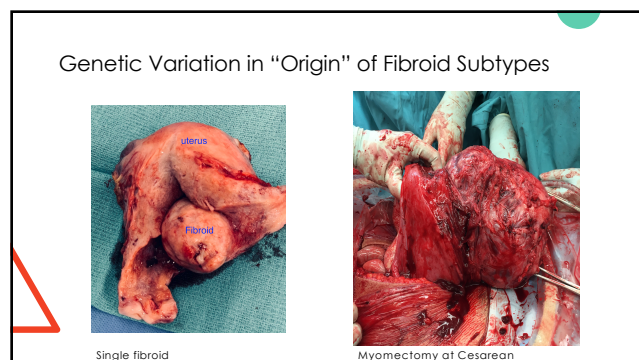
Hybrid Leiomyomas (impact both endometrium and serosa)	2-5	Submucosal and subserosal, each with less than half the diameter in the endometrial and peritoneal cavities respectively.
--	-----	---

Two numbers are listed separated by a dash. By convention, the first refers to the relationship with the endometrium while the second refers to the relationship to the serosa. One example is below

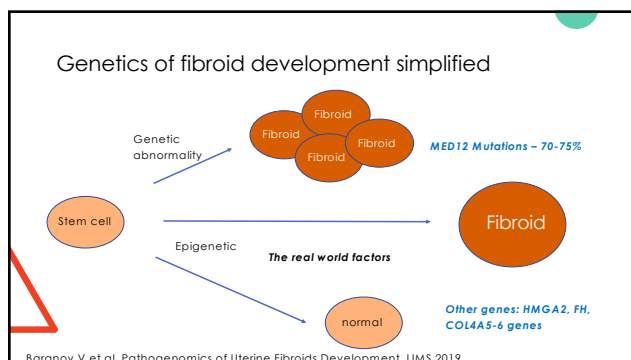
15



16



17



18

### Risk Factors

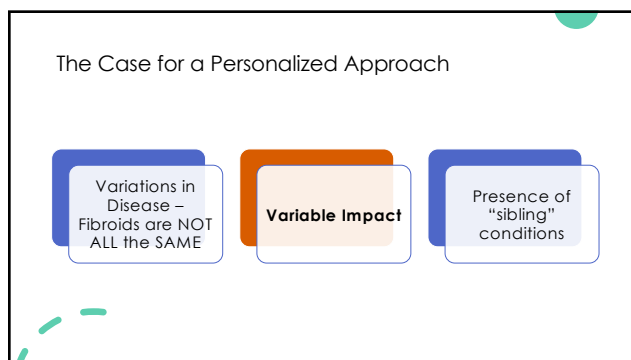
**Increased Risks**

- Race – Black
- Age
- Premenopausal status
- Hypertension
- Family history
- Time since last birth
- Food additive/soybean milk

**Reduced Risk**

- OCP or Injectable DMPA (contraception)
- Smoking in low BMI
- pregnancy

19



20

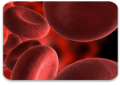


**Variable Impact**  
Start with Patient Goals


- Symptoms
- Fertility
- Expectations and Lived Experience

21


**Management Approach**



**Heavy Menstrual Bleeding/Anemia**  
Amenorrhea  
Reduced need for transfusion




**Fibroid Shrinkage**  
Improve access, may allow MIS  
Reduce blood flow, less intraop blood loss




**Pelvic Pain/Pressure Symptoms**  
Improve QoL  
Treatment while waiting for surgery

22


**Patient Experience**




Toronto Star 2014 June 13



The Ottawa Hospital 2014



Stock photo



**Flow Fighter**  
HOW I KICKED MY FIBROIDS & HEAVY PERIODS TO THE CURB  
Holly Bridges  
DON'T LET YOUR PERIODS RULE YOUR LIFE  
Available on Amazon

23

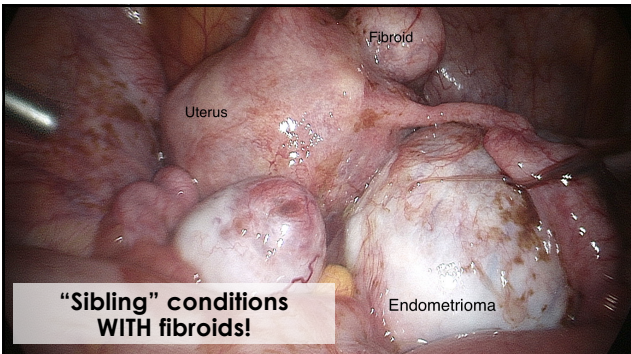
**The Case for a Personalized Approach**

Variations in Disease – Fibroids are NOT ALL the SAME

Variable Impact

Presence of “sibling” conditions

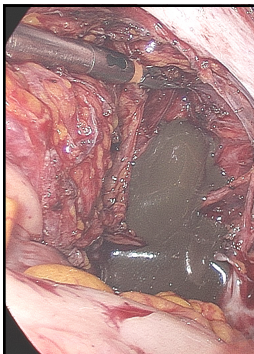
24



**“Sibling” conditions WITH fibroids!**

Labels: Uterus, Fibroid, Endometrioma

25



**Endometriosis and Fibroids**

- Up to 87% in one series of 208 patients treated for symptomatic fibroids found endometriosis!
- Consider it

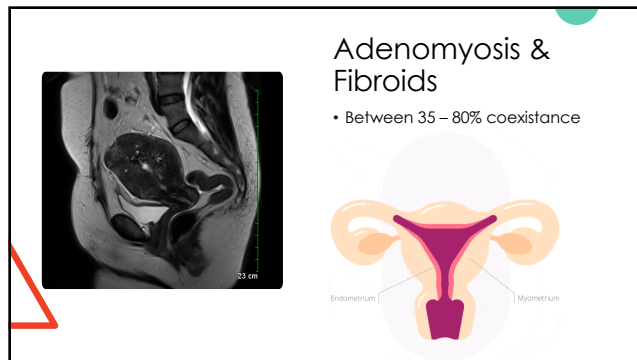
SCIENTIFIC PAPER **JSLs**

**Strong Association Between Endometriosis and Symptomatic Leiomyomas**


Connon Nezhat, MD, Anja Li, MD, Scapellato Albed, MD, Erila Robinson, MD, Rose Salemopol, BS, Azadeh Nezhat, MD, Ciano H. Nezhat, MD, Fani Nezhat, MD

Nezhat et al. JSLs 2016

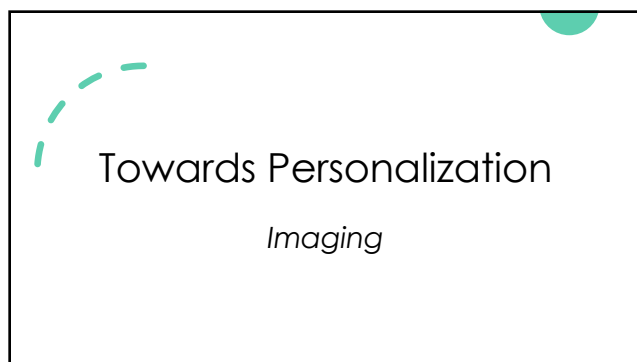
26



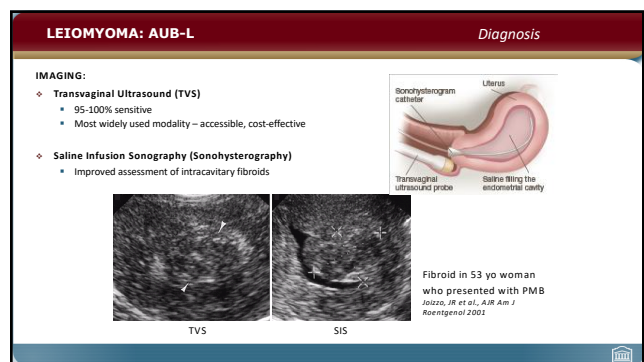
27



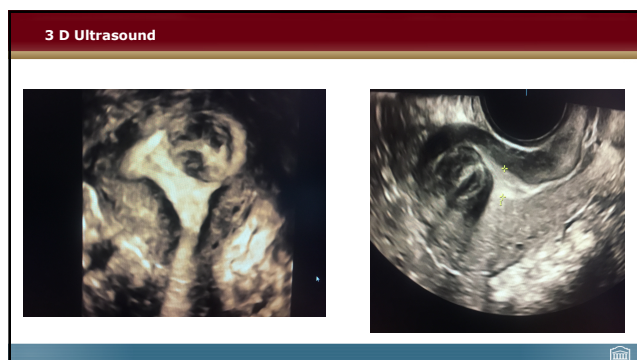
28



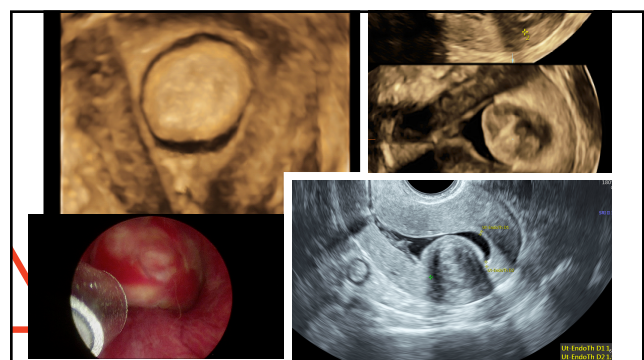
29



30



31

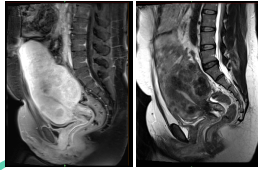


32



## MRI

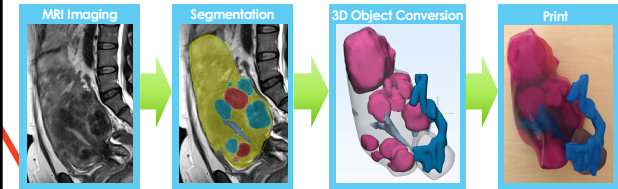
- Magnetic resonance imaging (MRI) and ultrasonography are often used for pre-surgical planning of complex gynecological cases



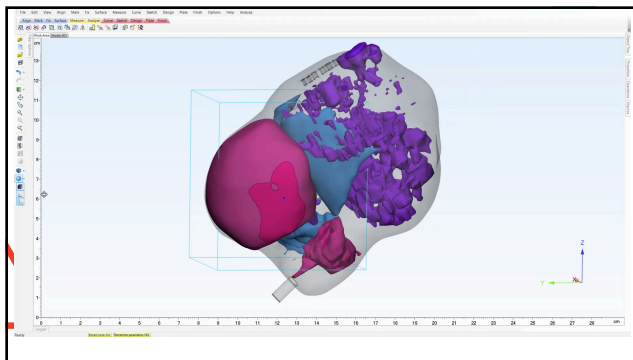
- MRI report:
  - Multi-fibroid uterus, ~10 x 10 x 16cm
  - Size and location descriptions of 3 "relevant" fibroids
  - One submucosal (FIGO type 2) displacing fundal region of endometrium inferiorly

33

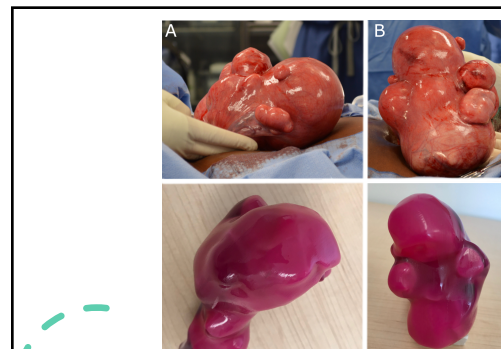
## 3D Printed Model Creation



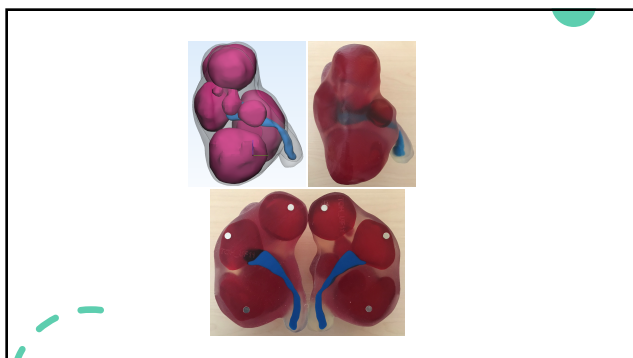34




35



36




37

3D PRINTING  
EXAMPLE

38

38



## Validity and Reliability of Ultrasound Elastography for the Characterization of Uterine Tissue Stiffness

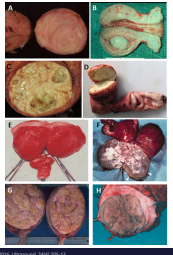
Cat Czynnyj  
Ph.D. Candidate  
Biomedical Engineering  
Supervisors: Drs. McLean & Labrosse

uOttawa

39

## Fibroids & Elastography

- Fibroids with microscopic changes<sup>1,2,3</sup>
  - Changes histological tissue properties
    - Cell density, ECM content, collagen content
  - May alter response to medical therapies
- Medical therapies<sup>4,5</sup>
  - Specific mechanisms of action
  - High non-response rates and adverse events
    - Ideal cases for medical treatment?
- Elastography
  - Tissue stiffness may relate to histology

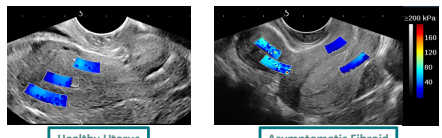


uOttawa

40

## Preliminary Results

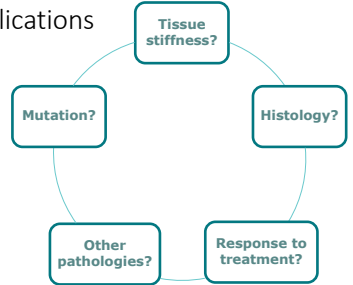
- Pilot Data



uOttawa

41

## Implications



uOttawa

42



## Summary

My dream


43

## Patient specific

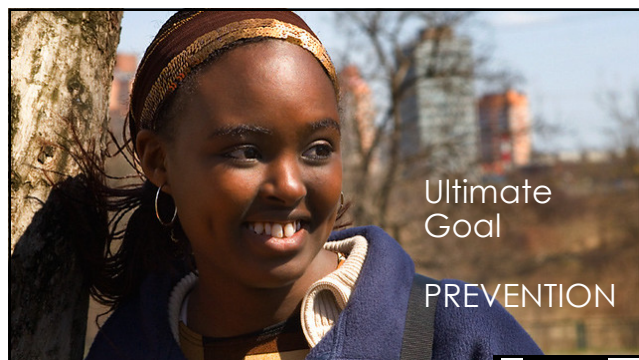## Fibroid specific

## Goal specific

The Right Choice  
For  
The Right Patient  
At  
The Right Time



44



45

### Conclusion

- There is significant heterogeneity among fibroids and patient presentations
- One size fits all approach to fibroid care is "behind the times"
- Innovations in diagnosis and Personalized Care should be prioritized

46

## Thank you

Sukhbir S. Singh MD, FRCSC  
Professor, Department of  
Ob/Gyn  
The Ottawa Hospital & University  
of Ottawa  
Canada

A photograph of a stone bridge over a river, with a large building in the background.

47